



A giant Lymphangioma circumscriptum on the flank: Case report

Alireza Sobhani¹ , Hakimeh S. Sajjadi^{1*} , Toubha Abbasi¹

1. Department of Pathology, Shahid Mohammadi Hospital, Hormozgan University of Medical Sciences, Bandar Abbas, Iran

*Correspondence: Hakimeh S. Sajjadi. Department of Pathology, Shahid Mohammadi Hospital, Hormozgan University of Medical Sciences, Bandar Abbas, Iran. Tel: +989171586080; Email: sajjadipathologyh@gmail.com

Abstract

Lymphangioma circumscriptum is a rare congenital proliferation of lymphatic vessels that may occur anywhere on the skin and mucous membranes. Based on the depth and the size of abnormal lymph vessels, these lesions are divided into two groups: the superficial vesicles are called lymphangioma circumscriptum, and the more deep-seated group includes cavernous lymphangioma, cystic hygroma, and benign lymphangi endothelioma. The differential diagnosis of lymphangioma includes herpes zoster, herpes simplex, molluscum contagiosum, Cutaneous Melanoma, Dermatitis Herpetiformis, and viral warts. We report here the rare case of giant cutaneous lymphangioma circumscriptum with emphasis on histopathology and differential diagnosis. Our case study was a 14-year-old boy with a history of multiple, clear, pink, red, and brown vesicles protruded as a patch of wart-like growths on the flank skin since he was 6 months old. The histopathologic examination consists of multiple thin-walled dilated lymphatic spaces in the papillary dermis lined with a single layer of endothelial cells filled with finely granular hyaline material.

Article History

Received: 21 May 2021

Received in revised form: 17 September 2021

Accepted: 22 December 2021

Published online: 23 August 2023

DOI:10.29252/mlj.17.4.28.

Keywords

Lymphangioma
Episeptum circumscriptum
Pathology
Skin

Article Type: Case Report



Introduction

Lymphangioma is a rare congenital proliferation of lymphatic vessels that can occur anywhere on the skin and mucous membranes. This malignancy manifests isolated or is associated with deep lymphangioma or angiodysplasia syndromes (Proteus, Cobb, or Maffucci) (1-3). Normal skin has no lymphatic channels in the papillary dermis. However, in Lymphangioma circumscriptum, dilated dermis channels protrude as a patch of wart-like growths on the skin (4).

Based on the depth and the size of abnormal lymph vessels, these lesions are divided into two groups: 1) the superficial vesicles, called lymphangioma circumscriptum and 2) the more deep-seated group, including Cavernous lymphangioma, cystic hygroma, and benign lymphangi endothelioma (3, 5-8). The pathogenesis of lymphangioma circumscriptum was first described by Whimster in 1976. He recognized that the cause of vesicles on surface skin is contraction and pressure of muscle fibers of the lining of lymphatic cisterns in the deep subcutaneous tissue that protrudes from the skin's surface and becomes vesicles (9). We report a rare case of cutaneous lymphangioma circumscriptum with emphasis on histopathology and differential diagnosis.

Case presentation

A 14-year-old boy presented to the pathology Clinic at Shahid-Mohammadi Hospital Center of Bandar Abbas, Iran. The boy had a history of multiple, clear, pink, red, and brown vesicles on the left flank since he was 6 months old. According to him, he had experienced recurrent infections of this area that had been treated with multiple courses of antibiotics.

Physical examination

We observed well-defined, irregular, brownish plaque of 150 × 40 mm covered by multiple clusters of 1-20-mm, clear, pink, and brown vesicle-like verrucous changes on the left flank skin (Figure 1).

Histopathology

On histopathologic examination, lesions of superficial lymphangioma consist of multiple thin-walled, dilated lymphatic spaces in the papillary dermis lined with a single layer of endothelial cells filled with finely granular hyaline material. The overlying epidermis is thin, hyperkeratotic, and acanthosis with an irregular elongation of the rete ridge. No atypical vascular features, nuclear atypia, mitotic activity, or koilocytic changes were observed. Also, there was a mild to moderate inflammatory infiltrate within a fibroblastic or collagenous stroma, which may contain lymphocytes with no penetration of muscle (Figure 2).

Discussion

Lymphangiomas are a rare congenital proliferation of lymphatic vessels. They occur as localized or generalized malformations in the skin and mucous surfaces, especially the head and neck, proximal extremities, buttocks, chest, armpits, and oral cavity (1-3). The most common form of cutaneous lymphangioma is lymphangioma circumscriptum, which arises in infancy but may occur at any age. In 90% of cases, it arises until two years of age. It accounts for approximately 4% of vascular tumors and 26% of benign vascular tumors in children. Based on the depth and the size of abnormal lymph vessels, these lesions are divided into two groups: 1) superficial vesicles called lymphangioma circumscriptum and 2) the more deep-seated group, including cavernous lymphangioma, cystic hygroma, and benign lymphangi endothelioma (2-6).

Clinical findings consist of multiple, clear vesicles of 2 - 4 mm similar to frog spawns that may be pink, red, or brown due to hemoglobin degradation. These vesicles contain lymph fluid caused by abnormal dilations of lymph vessels (3, 6, 7, 10). For a definite diagnosis of lymphangioma circumscriptum, histopathological examination is advised. This examination represents the dilated lymphatic vessels in the papillary dermis, extending to the reticular dermis and subcutaneous tissue. The lumen is filled with finely granular hyaline material and red blood cells, lymphocytes, macrophages, or neutrophils (2, 3, 6, 7, 11, 12). Indications of treatment include cosmetic appearance and prevention of complications such as cellulitis. The choice treatment is surgical excision, while the other palliative treatments are sclerotherapy, cauterization, cryotherapy, radiotherapy, CO2 laser, and thermoablation. About 75% of the patients are cured, and it has a low rate of recurrence. However, the recurrence rates can be high, especially in the lesions with deeper components (2, 3, 13-15). The differential diagnosis used for this purpose includes herpes zoster, herpes simplex, molluscum contagiosum, Cutaneous Melanoma, Dermatitis Herpetiformis, viral warts, angiosarcoma, hemangioma, epidermal nevus, angiokeratoma, metastatic carcinoma of the skin, Neurofibromatosis Type 1, Dabska Tumor, and Stewart-Treves Syndrome.

Conclusion

Lymphangioma circumscriptum is a rare congenital proliferation of lymphatic vessels that may occur anywhere on the skin and mucous membranes and its main differential diagnosis included herpes zoster, herpes simplex, Cutaneous Melanoma and Dermatitis Herpetiformis that histology is considered as a gold standard for definite diagnosis. Our findings can contribute to more accurate diagnostic processes and launch new researches in the future.

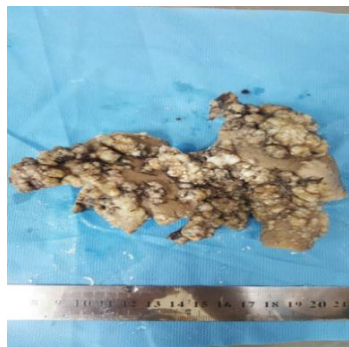


Figure 1. Multiple clusters of 1-20-mm, clear, and brown vesicle

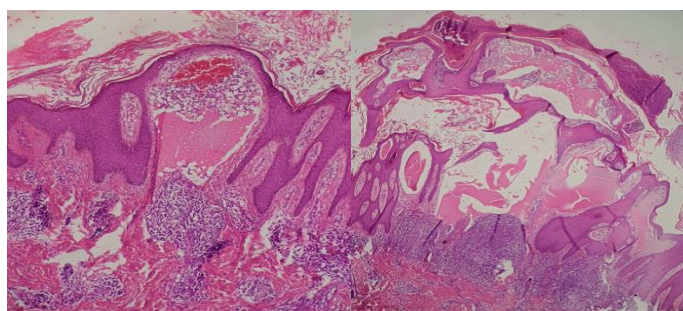


Figure 2. Microscopic feature lymphangioma with multiple dilated lymphatic vessels in the dermis containing finely granular hyaline material (Hematoxylin and eosin stain, original magnification $\times 100$)

Acknowledgement

The authors wish to thank all the personnel of department of pathology of Hormozgan University of Medical Sciences.

Funding sources

This research received no specific grant from any funding agency.

Ethical statement

In relation to ethical considerations, informed consent was obtained from the parents of the patient.

Conflicts of interest

None declared.

Author contributions

All authors contributed to the study conception and design. All authors contributed to the article and approved the submitted version.

References

1. Stewart C, Chan T, Platten M. Acquired lymphangiectasia ('lymphangioma circumscriptum') of the vulva: a report of eight cases. *Pathology*. 2009;41(5):448-53. [[View at Publisher](#)] [[DOI](#)] [[PMID](#)] [[Google Scholar](#)]
2. Fatima S, Uddin N, Idrees R, Minhas K, Ahmad Z, Ahmad R, et al. Lymphangioma circumscriptum: clinicopathological spectrum of 29 cases. *Journal of the College of Physicians and Surgeons Pakistan*. 2015;25(9):658-61. [[View at Publisher](#)] [[PMID](#)] [[Google Scholar](#)]
3. Patel GA, Schwartz RA. Cutaneous lymphangioma circumscriptum: frog spawn on the skin. *International journal of dermatology*. 2009;48(12):1290-5. [[View at Publisher](#)] [[DOI](#)] [[PMID](#)] [[Google Scholar](#)]
4. Kokcam I. Lymphangioma circumscriptum of the penis: a case report. *Acta dermatovenerologica alpina panonica et adriatica*. 2007;16(2):81. [[View at Publisher](#)] [[PMID](#)] [[Google Scholar](#)]
5. Elder DE. Tumors of the epidermal appendages. *Lever's Histopathology of the Skin*. 1997:786-9. [[View at Publisher](#)] [[Google Scholar](#)]
6. Zaballos P, del Pozo LJ, Argenziano G, Karaarslan IK, Landi C, Vera A, et al. Dermoscopy of lymphangioma circumscriptum: a morphological study of 45 cases. *Australasian Journal of Dermatology*. 2018;59(3):e189-e93. [[View at Publisher](#)] [[DOI](#)] [[PMID](#)] [[Google Scholar](#)]
7. Massa AF, Menezes N, Baptista A, Moreira AI, Ferreira EO. Cutaneous Lymphangioma circumscriptum-dermoscopic features. *Anais brasileiros de dermatologia*. 2015;90(2):262-4. [[View at Publisher](#)] [[DOI](#)] [[PMID](#)] [[Google Scholar](#)]
8. Gencoglan G, Inanir I, Ermertcan A. Hypopyon-like features: new dermoscopic criteria in the differential diagnosis of cutaneous lymphangioma circumscriptum and haemangiomas? *Journal of the European Academy of Dermatology and Venereology*. 2012;26(8):1023-5. [[View at Publisher](#)] [[DOI](#)] [[PMID](#)] [[Google Scholar](#)]
9. Whimster I. The pathology of lymphangioma circumscriptum. *British Journal of Dermatology*. 1976;94(5):473-86. [[View at Publisher](#)] [[DOI](#)] [[PMID](#)] [[Google Scholar](#)]
10. SCOPE A, Amini S, Kim NH, Zell DS, Oliviero MC, Rabinovitz HS. Dermoscopic-histopathologic correlation of cutaneous lymphangioma circumscriptum. *Archives of dermatology*. 2008;144(12):1671-2. [[DOI](#)] [[PMID](#)] [[Google Scholar](#)]
11. Rapini R. *Practical Dermatopathology; Chapter 27- Fibrohistiocytic proliferations and neoplasms*. 2005:341-56. [[View at Publisher](#)] [[DOI](#)] [[Google Scholar](#)]
12. Eliezri YD, Sklar JA. Lymphangioma circumscriptum: review and evaluation of carbon dioxide laser vaporization. *The Journal of dermatologic surgery and oncology*. 1988;14(4):357-64. [[View at Publisher](#)] [[DOI](#)] [[PMID](#)] [[Google Scholar](#)]
13. Lapidoth M, Ackerman L, Amitai DB, Raveh E, Kalish E, David M. Treatment of lymphangioma circumscriptum with combined radiofrequency current and 900 nm diode laser. *Dermatologic surgery*. 2006;32(6):790-4. [[View at Publisher](#)] [[DOI](#)] [[PMID](#)] [[Google Scholar](#)]
14. Bikowski JB, Dumont AMG. Lymphangioma circumscriptum: treatment with hypertonic saline sclerotherapy. *Journal of the American Academy of Dermatology*. 2005;53(3):442-4. [[View at Publisher](#)] [[DOI](#)] [[PMID](#)] [[Google Scholar](#)]
15. Okazaki T, Iwatani S, Yanai T, Kobayashi H, Kato Y, Marusasa T, et al. Treatment of lymphangioma in children: our experience of 128 cases. *Journal of pediatric surgery*. 2007;42(2):386-9. [[View at Publisher](#)] [[DOI](#)] [[PMID](#)] [[Google Scholar](#)]

How to Cite:

Sobhani A, Sajjadi H, Abbasi T. A giant Lymphangioma circumscriptum on the flank: Case report. *Med Lab J*. Jul-Aug 2023;17(4):28-9.



© The author(s)